

# Chapter-4

## Human Anatomy & Physiology

### D.Pharma 1<sup>st</sup> Year Notes

#### Chapter- 4

#### Osseous system:

- Structure and functions of bones of axial and appendicular skeleton Classification, types and movements of joints, disorders of joints

**OSSEOUS SYSTEM:**

**STRUCTURE AND FUNCTIONS OF BONES OF AXIAL AND APPENDICULAR SKELETON CLASSIFICATION, TYPES AND MOVEMENTS OF JOINTS, DISORDERS OF JOINTS**

Human Anatomy and Physiology **CHAPTER- 5**

We Learn About This Topic

- Osseous system: structure and functions of bones of axial and appendicular skeleton Classification, types and movements of joints, disorders of joints

**ONE SHOT COMPLETE VIDEO**

According to New Syllabus D.Pharma 1<sup>st</sup> Year की पूरी जानकारी हिंदी में

Download PDF notes Visit our Website

[www.noteskarts.com](http://www.noteskarts.com)

Video Dekhne Ke Liye QR scan Kare

43.9K views



## Osseous System/Skeleton system:

The human skeleton is the internal framework of the human body and composed of Bone, cartilage, joints, ligaments, tendons accounts for about 20% of body mass.

### Bone:

- Bone is rigid connective tissue that constitutes the minerals, calcium phosphate, collagen.
- Bone protects the various organs of the body, produce the blood cells, store minerals, provide structure and support for the body.
- It is composed of around 270 bones and reduces to around 206 bones by adulthood after some bones get fused together.

### Cartilage:

- Cartilage is the non vascular type or supporting connective tissue which provide the flexibility to the body organs and joining the one organ to another.
- Cartilage occurs only in isolated areas, such as the nose, parts of ribs, and joints.

### Ligaments:

- Ligament is also a fibrous type of connective tissue and connects the one bone to another bone.

### Joints:

- Joint or articulation is connect the one bone to another and provide the bending ability.

### Tendons:

- Tendon is a cord of strong flexible connective tissue, which joins the bone to the body muscle.

**Human skeleton system divided into two parts—**

1. **The Axial skeleton.**
2. **The Appendicular skeleton.**



## 1. The axial skeleton:

- Axial skeleton forms the longitudinal axis of the body and protects the brain, spinal cord, and the organ in the thorax.
- It provides support to the head, neck, and trunk. Axial skeleton are composed by the 80 bones segregated into three major regions.

### A. Skull Bone.

### B. Vertebral column.

### C. Thoracic cage.

## A. Skull bone.

Skull bone are flatted and firmly united by interlocking joints called sutures but mandible bone which is connected to the rest of the skull freely movable bones.

The skull region articulates with the superior region of vertebral column with the help of two occipital condyles (Dicondylic skull).

The skull is the most complex structure of the human body.

It consists of 22 bones and forms the hard protective outer covering for brain tissue. It is further divided into two parts.

- **The cranial bone**—Cranial bone consists of 8 number of bones. Frontal bone(1), Parietal bone(2), Temporal bone(2), Occipital bone(1), Sphenoid(1), Ethmoid(1).
- **The facial bone**—Mandible(1), Vomer(1), maxilla(2), Zygomatic bone(2), palatine bone(2), Nasal bone (2), Lacrimal bone(2), inferior nasal concha(2).

## Functions of Skull bone—

- It provides the framework for the face and cranial.
- Provide the opening for food and air passage.
- Bones contains the cavities for special sense organ of sight, taste and smell.
- Socket formation for the teeth
- Protect the most important processing unit of brain.

## Sutures of the skull bone—

- Coronal suture— Parietal bone and Frontal bone.
- Sagittal suture— Parietal bone and parietal bone.
- Lambdoid suture— Parietal bone and Occipital bone.
- Squamous suture—Parietal bone and Temporal bone.

**Note:** Some associates bones are present in the skull. It does not count in the skull bone.

- **Ear ossicles/Auditory ossicles**— Ear ossicles help in the hearing process. It consists of three bones: - Malleus(hammer), Incus(Anvil), Stapes(Stirrup).
- **Hyoid bone**— It is small bone present at the joint end of tongue and provide the joint surface for tongue.

## Vertebral column.

Vertebral column also called as spine or spinal column, it consists of 26 irregular serially arranged unit called as vertebrae and dorsally placed.

In the fetus and infants, the vertebral column consists of 33 separate bones or vertebrae.

In adult age , nine of these eventually fuse to form two composites bones, the sacrum and coccyx the remaining 25 bones persists at individual vertebrae separates by intervertebral discs.

All vertebrae have a common pattern. Each vertebra consists of a body or Centrum anteriorly and a vertebrae arch posteriorly.

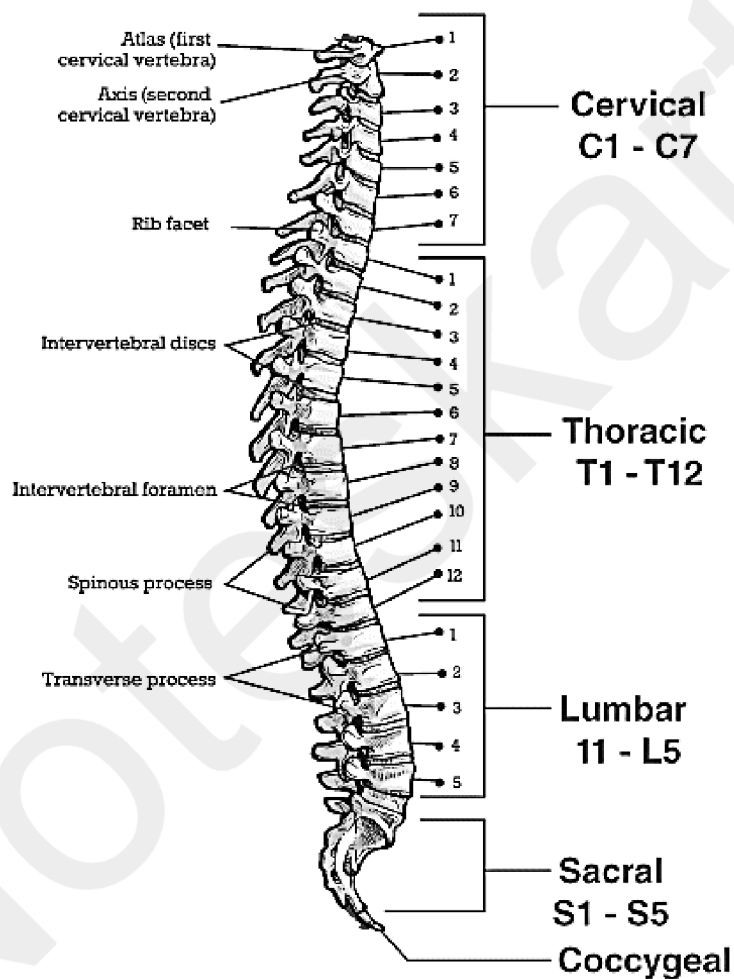
Together, the body and vertebrae arch enclose an opening called the vertebral foramen. Successive vertebrae foramen of the articulated vertebrae from the long vertebrae canal, through which the spinal cord passes.

- The Vertebral column differentiated into—  
Cervical (7), Thoracic (12), Lumber (5), Sacral (1-Fused), Coccygeal (1-Fused).

Subscribe & Visit our Website For Notes

## Functions of vertebral column—

- The vertebral column protects the spinal cord, supports the head and serves as the point of attachment for the ribs and musculature of the back.
- The vertebral column extends from the skull to pelvis, where it transmits the weight of the trunk to the lower limbs.



## Thoracic cage bone.

Thoracic cage consists, thoracic vertebrae posteriorly, the ribs laterally, and sternum anteriorly.

**Sternum**— It is also called breast bone. Sternum is a flat bone about 15cm long present on the anterior position of the thoracic cage. It is formed by the fusion of three bones- Manubrium, the body, and Xiphoid process.



Subscribe & Visit our Website For Notes

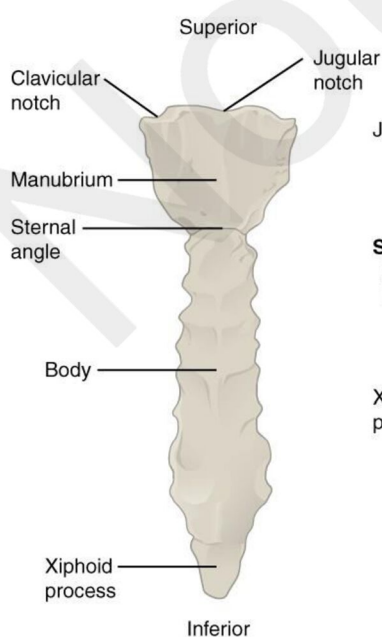
- The manubrium articulates via its clavicular notches with the clavicle bone laterally and just below this, it also articulates with the first two pairs of ribs.
- Body forms the major portion of the sternum and it's providing the attachment site for three to seven ribs.
- Xiphoid is the end or small portion of sternum and serve as an attachment point for some abdominal muscles.

**Ribs**— 12 pairs of ribs present in the human body. Each rib is posteriorly connected with vertebral column and anteriorly sternum.

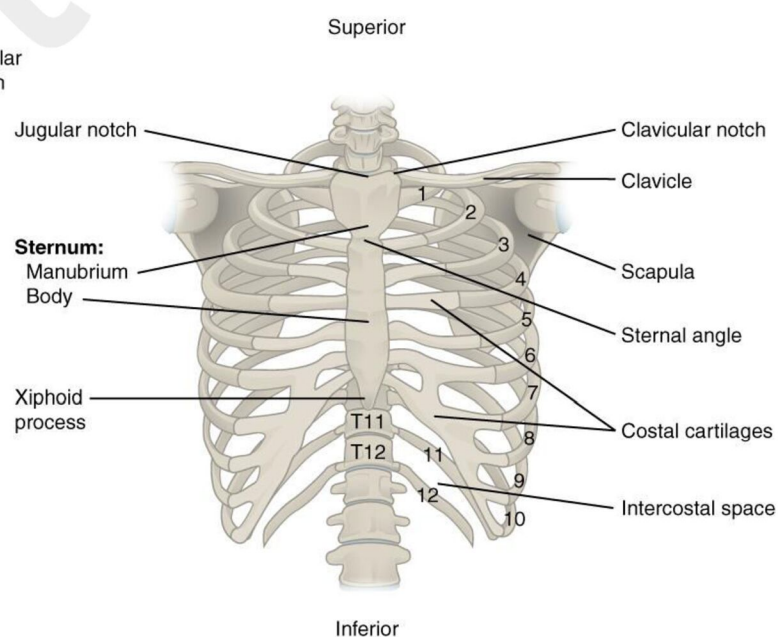
- First seven pair of ribs are called true ribs or vertebrosteral ribs because they are attached to the thoracic vertebrae anteriorly and sternum posteriorly with the help of hyaline cartilage.
- The 8<sup>th</sup> , 9<sup>th</sup> and 10<sup>th</sup> pairs of ribs do not articulate directly with the sternum but join the seven rib with the help of hyaline cartilage these are called vertebrochondral (False) ribs.
- Last 2 pair (11<sup>th</sup> and 12<sup>th</sup> ) of ribs are not connected ventrally and are therefore called floating ribs.

### Function of thoracic cage—

- It protects the vital organs (Heart, lungs, and blood vessels). It provide the support for shoulder , upper limbs and also provide attachment points for many muscle of the neck, back, chest, shoulder.



(a) Anterior view of sternum



(b) Anterior view of skeleton of thorax

## The Appendicular Skeleton.

Bones of the limbs and their girdle are collectively called the Appendicular skeleton. Appendicular skeleton consists of—

1. Pectoral girdle.
2. Upper limbs.
3. Pelvic girdle.
4. Lower limbs.

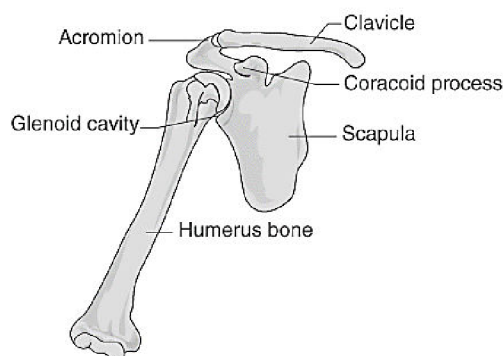
### 1. Pectoral girdle.

Each pectoral girdle consists of a clavicle bone (anterior) and a scapula (posterior).

- Clavicles or collar bone are slender S-shaped bone. They articulate posteriorly with scapula and arms and anteriorly with sternum.
- Scapula is a large triangular flat bone situated in the dorsal parts of the thorax between the second and seventh ribs.
- Scapula consists of three structure—Spine, acromian process, coracoid process.
- The acromian articulates with the acromial end of the clavicle forming the acromioclavicular joints.
- Below the acromian present a depression called the glenoid cavity which articulates with the head of the humerus to form the shoulder joints.

### Functions of pectoral girdle—

- The pectoral girdle attaches the upper limbs to the axial skeleton and provides attachment site for many muscles that move the upper limbs.
- The socket of shoulder joint allows the upper limbs articulation and degree of mobility.



## 2. Upper limbs.

Each upper limbs consists 30 bones. It is categories into three parts.

### a. **Arm**—

- Humerus is sole bone of arm, its proximal end articulate to the glenoid cavity of the scapula.
- Humerus head consists of lesser tubercle, and just inferior to this lateral greater tubercle. It helps in muscle attachment.
- V-shaped deltoid tuberosity are present in the midway, they provide the roughed attachment site for the deltoid muscle of the shoulder.

### b. **Fore arm**—

- Forearm consists of two parallel bone radius and ulna. Their proximal end articulate with the humerus and distal end forms joints with bones of wrist.
- The radius and ulna articulate with each other by radioulnar joints and they are connected along their entire length by a flat flexible ligament, the interosseous membrane.

### c. **Hand**— Its consists of 3 types of bone.

- **Carpal**— Carpal consists of eight numbers of bones which are closely united by the ligaments. [Scaphoid, lunate, triquetrum, pisiform] [trapezium, trapezoid, capitates, hamate].
- **Metacarpals**—Metacarpal consists of five bones. The base of the metacarpals articulates with the carpals and head articulate with the phalanges of fingers.
- **Phalanges**— Phalanges consist of 14 bones. Except for the thumb each fingers has three phalanges- Distal, middle, and proximal. The thumb has no middle phalange.

# Share With Your Friends





Subscribe & Visit our Website For Notes

## 3. Pelvic Girdle/Hip girdle.

Pelvic girdle consists of irregularly shaped three separated bones during childhood, the ileum, ischium, and pubis.

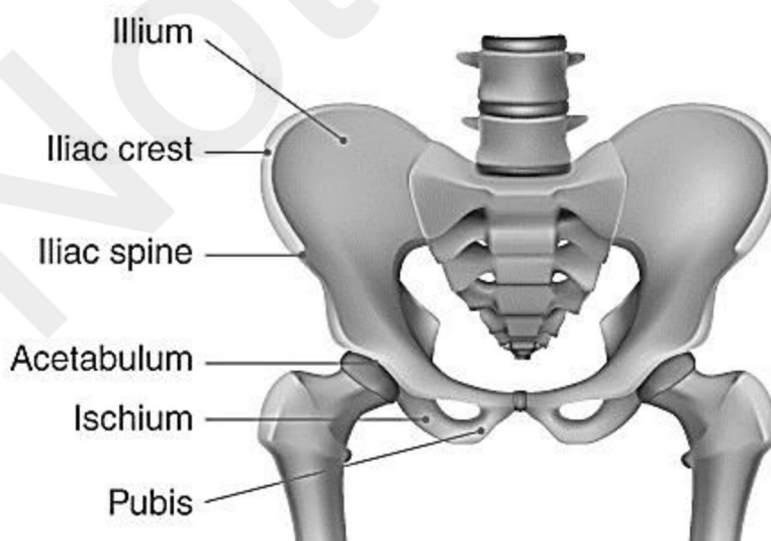
In adults, these bones are firmly fused and their boundaries are indistinguishable. Each hip unites with its partner anteriorly and with the sacrum posteriorly.

- **Ilium:** The Ilium is a large flaring bone that forms the superior region of the hip bone. The broad posterolateral surface of the ilium, the gluteal surface is crossed by three ridges, posterior, anterior, and inferior gluteal line, to which the gluteal muscle attaches.
- **Ischium:** It is the general l-shaped or arc shaped bone. It has a thicker superior body adjoining the ilium and a thinner inferior ramus. The ramus joins the pubis anteriorly.
- **Pubis:** It forms the anterior portion of the hip bone. It is V- shaped bone. The body of the two pubis bones are joined by a fibro cartilage, disc forming the midline pubis symphysis joints.

### Functions of pelvic girdle—

The pelvic girdle attaches the lower limbs to the axial skeleton transmits the complete weight of the upper body to the lower limb, and supports the visceral organs.

It also support provide during the birth of baby.



## 4. The Lower Limb bone.

Each Lower limb consists of 30 bones. It is divided into three segments.

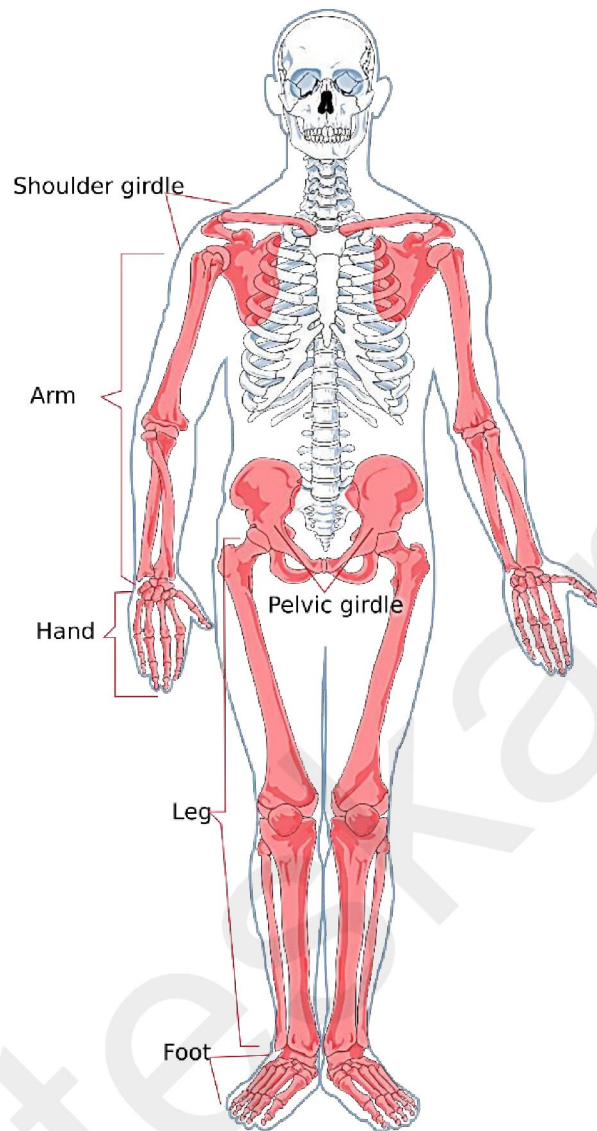
1. **Thigh**— The femur is the sole bone of the thigh, it is the longest, largest bone of the body. Its length is roughly  $\frac{1}{4}$  of a person's height.
  - Proximally the femur articulates with the hip bone. The ball-like head of the femur has a small central pit called the fovea capitis.
  - The thigh consists of the lateral greater trochanter and the posteromedial lesser trochanter; these projections serve as sites of attachment for thigh muscles.

**Note:** - The patella is a cup-shaped bone enclosed in the tendon that secures the anterior thigh muscles to the tibia. It protects the knee joints anteriorly and improves the leverage of the thigh muscles acting across the knee.

2. **Leg**—The leg consists of the two parallel bones, the tibia and fibula; these bones are connected with each other by the help of the interosseous membrane. Proximally, the tibia attaches to the femur bone and distally with the talus bone of the foot at the ankle.
3. **Foot**— It consists of the three bones:
  - A. **Tarsals:**
    - It consists of the seven bones that form the posterior half of the foot. Body weight is carried primarily by the two largest posterior tarsals.
    - The talus, which articulates with the tibia and fibula superiorly and the strong calcaneus, which forms the heel of the foot and carries the talus on its superior surface.
  - B. **Metatarsals**—
    - The metatarsus consists of five small bones called metatarsals. The first metatarsal, which plays an important role in supporting body weight.
  - C. **Phalanges**—
    - 14 phalanges of the toes are present in the foot. These are three phalanges in each digit except for the great toe, the hallux. The hallux has only two, proximal and distal.

# Share With Your Friends





### Movement:

- **Movement** is the characteristic feature of the living organisms, by the movement of limbs, jaws, eyelids, tongue, etc human beings perform walking, running, climbing, flying, swimming, locomotion.
- Locomotion and movement are linked term but all locomotion's are movement but all movement are not locomotion.

### Types of movement present in human being—

- A. **Amoeboid movement**— Some specialized cells in our body like microphages and leucocytes in blood exhibit amoeboid movement. It is perform by the pseudopodia formation by the streaming of protoplasm.

Cytoskeleton elements like microfilaments are also involved in amoeboid movements.

**B. Ciliary movement**— Ciliary movement occurs in the most of our internal tubular organs which are lined by ciliated epithelium. The coordinate movement of cilia in trachea helps us in removing dust particles. Passage of ova through the female reproductive tract is also facilitated by the ciliary movements.

**C. Muscular movement**—Movement of our limbs jaws, tongue, etc require muscular movement. The contractile property of muscle is effectively participating in the locomotion and other movements by human being and majority of multi cellular organisms.

## **Joints/Articulations.**

- The study of joints is called→**Anthrology.**
- Replacing diseased joints with an Artificial joint is called→**Arthroplasty.**
- Joints are point of contact between bones or between bones and cartilage. Forces generated by the muscles are used to carry out movement through joints. Where the joint act as a fulcrum.
- Our joints have two fundamental functions, they give our skeletal mobility and they hold it together. Joints are divided into **two categories**—

### **A. On the basis of function of joint it is divided into three parts.**

- I. **Synarthroses**— It is the immovable type of joint present in the fibrous joints. It is mainly present in the axial skeleton.
- II. **Amphiarthroses**— It is the slightly movable type of joint present in the cartilaginous joint. It is also restricted in the axial skeleton.
- III. **Diarthroses**— It is the movable type of joint present in the synovial joints. Movable joint predominate in the appendicular skeleton (limbs).

### **B. On the basis of structure of joint it is divided into three parts—**

- The structural classification mainly based on the material binding the bone together and whether, or not a joint cavity is present.



- Only synovial joints have a joint cavity.
- I. **Fibrous joint**— In this joint bones are joined by the collagen fibers of connective tissue and do not allow any movement. Fibrous joint further classified into three parts—
  - **Sutures**— This type of joint is shown by the flat skull bones which fuse end- to- end with the help of dense fibrous connective tissue. The wavy articulating bone edge interlock and the junction is completely filled by a less amount of very short connective tissue fibers. During middle age the fibrous tissue ossifies and the skull bones fuse into a single unit. At the puberty stage, the closed sutures are called synostoses.
  - **Syndesmoses**— In syndesmoses the bones are connected exclusively by ligaments cord or band of fibrous tissue. The connecting fibers are always longer than those in suture and allowed large amount of movement than suture.
  - **Gomphosis**— A gomphosis is a peg- in –socket fibrous joint. The only example is the articulation of the tooth with its bony alveolar socket.
- II. **Cartilaginous joint**— In this joint bone are joined together with the help of cartilage. Like, fibrous joints, they lack a joint cavity and are not highly movable. The two types of cartilaginous joint shows—
  - **Synchondroses**— The hyaline cartilage plate are joined the bone to each other.
    - Example- Joint between the costal cartilage of the first rib and the manubrium.  
Epiphyseal plate in long bone of children.
  - **Symphyses**— A joint where fibro cartilage unites the bone as a symphyses, since fibro cartilage is compressible and acts as a shock absorber and permits a limited amount of movement of joint.  
**Example-** Joint between the adjacent vertebrae in the vertebral column (Intervertebral joint).



Pubic symphysis of the pelvis.

### III. Synovial joint—

- Synovial joint are characterized by the presence of a fluid filled synovial cavity between the articulating surfaces of the two bones.
- This arrangement permits the considerable movements. Synovial cavity contains a small amount of slippery synovial fluid occupies all free spaces within the joint capsules.
- Synovial fluid has a viscous due to hyaluronic acid secreted by cells in the synovial membrane, but it thins and become less viscous during joint activity.

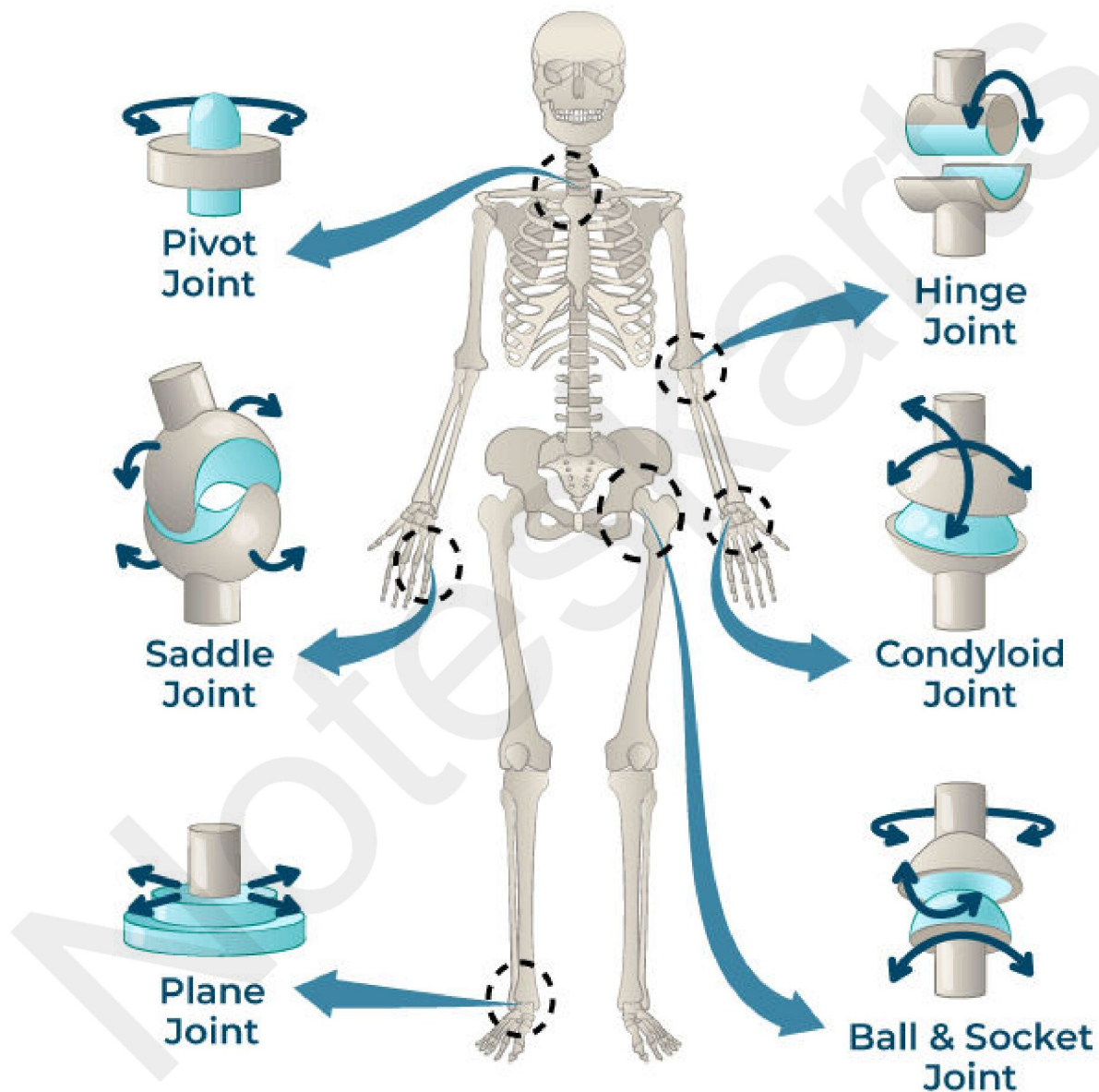
### On the basis of movement synovial joints are classified in many parts-

- a) Ball and socket joint—** The head of one bone is ball-shaped are articulates with a cup shaped socket of another bone. These joint are allow wide range of movements including, Flexion, extension, adduction, abduction, rotation, and circulation. Example: - Between humerus and pectoral girdle, between femur and pelvic girdle.
- b) Hinge joint—** The articulating ends of the bone fits together like a hinge on a door, and movement is therefore restricted to flexion, extension. Example: - Knee joint, Elbow joint, Ankle joint, inter phalangeal joint.
- c) Gliding joint—** The articular surface are flat or very slightly curved and slide over one another, but the amount of movement possible is very restricted, this group of joints is the least movable of all the synovial joints. Example: - between carpal bone, between tarsal bone, between vertebral body and cartilaginous disc.
- d) Pivot joint—** These joints allow a bone or a limb to rotate. One bone fit into a hoop-shaped ligament that holds it close to another bone and allows it to rotate in the ring. Example- between atlas and axis of cervical vertebrae.
- e) Condylloid joint—** A condyle is a smooth rounded projection on a bone and in a condylloid joint, it sits within a cup-shaped depression on the other bone. Example: - Metacarpals and phalanges of hand,

Subscribe & Visit our Website For Notes

Metatarsals and phalanges of foot, Condylar process of the mandible and the temporal bone.

- f) **Saddle joint**— The articulating bones fit together like a man sitting on a saddle. The most important saddle joint is at the base of the thumb, between the trapezium of the wrist and the first metacarpal bone.



## Share With Your Friends



## Disorders of the bone and joints.

1. **Arthritis**—Inflammation of the joint.
2. **Rheumatoid Arthritis**—
  - It is the chronic progressive inflammatory autoimmune disorder in which the body immune system attacks its own tissue.
  - The initial trigger for this reaction is unknown but various bacteria and viruses have been suspected.
  - Rheumatoid arthritis begins with inflammatory of the synovial membrane of the affected joints. Inflammatory cells migrate into the joint cavity from the blood and unleash a deluge of inflammatory chemicals that destroy body tissue when release in large amount.
  - For the Rheumatoid treatment many steroidal and non-steroidal anti-inflammatory drugs helps in decreasing pain and inflammation, increasing joint mobility. More powerful immune suppressants (Methotrexate) act to slow the auto immune reaction.
3. **Osteoarthritis**— This is a degenerative non-inflammatory disease that results in pain and restricted movement of affected joints in which, progressively loss or degeneration of articular cartilage, resulting in the cyst formation, limitation of motion, deformity, and progressive disability at the margin of joints. Inflammation may or may not be present in the affected joints.
4. **Psoriasis arthritis**— Psoriasis is one of a group of disorders known as the spondylo arthropathis. Psoriatic arthritis affects some people who have psoriasis, a disease that cause red patches of skin topped with silvery scales at the joint points. It also causes the itching and some time inflammations are appear.
5. **Bursitis**—Bursitis is a painful condition that affects the small fluid filled sacs called bursae. Bursae are fibrous sacs lined with synovial membrane and containing synovial fluid. The most common locations for bursitis are in the shoulder, elbow and hip.
6. **Gout**— Uric acid is the normal waste products of nucleic acid metabolism is ordinarily excreted in urine without any problems. However, when blood levels of uric acid rise excessively, it may be deposited as needle-shaped urate crystal in the soft tissue of joints.

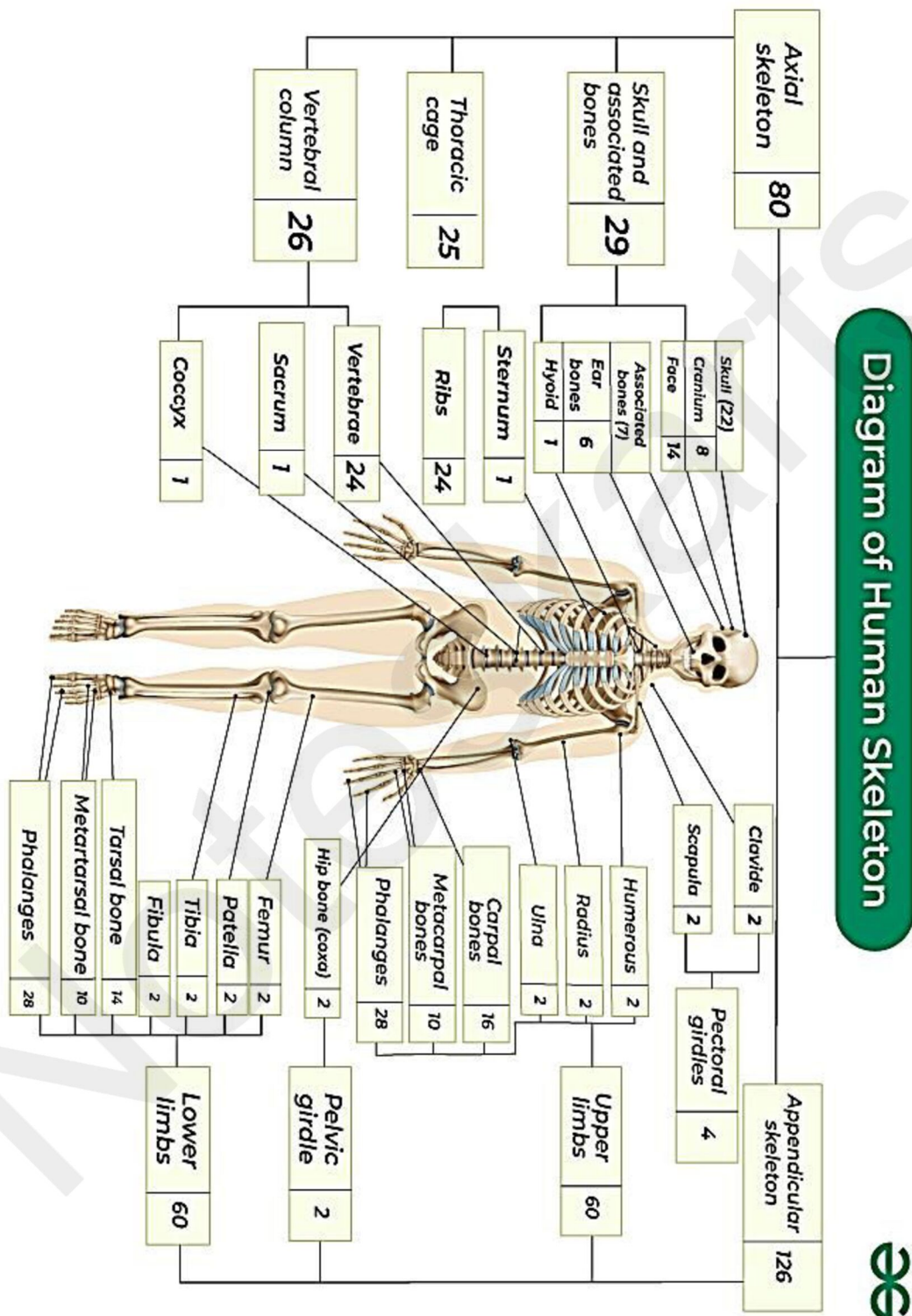
- An inflammatory response follow, leading to agonizingly painful attacks of gouty arthritis or gout. The initial attack typically affects on joint often at the base of the great toe.
  - Gout is for more common in men than in women because men naturally have higher blood levels of uric acid. Untreated gout can be very destructive, the articulating bone ends fuse and immobilize the joints.
  - Patients are advised to drink plenty of water and to avoid excessive alcohol consumption. Several drugs colchicines, non-steroidal, anti- inflammatory drugs, glucocorticoids, and others the terminate or prevent gout attacks.
7. **Lyme disease**— Lyme disease is an inflammatory disease caused by spirochete bacteria transmitted by the bite of ticks that live on mice and deer. It often results in joint pain and arthritis especially in the knees, and is characterized by a skin rash, flu-like symptoms and foggy thinking. Antibiotic therapy is the useful treatment.
  8. **Osteoporosis**— Age related disorder characterized by decreased bone mass and increased chances of fractures. It is widely seen in the female than male due to decreased levels of estrogen in female.
  9. **Paget's disease**— Paget's disease is a disorder of bone remodeling, where the normal balance between bone building and bone breakdown becomes disorganized and both osteoblasts and osteoclasts become abnormally active. The bone deposited is soft and structurally abnormal. This predisposes to deformities and fractures, commonly of the pelvis, femur, tibia and skull.
  10. **Reiter's syndromes**— This syndrome may be precipitated by *Chlamydia trachomatis* infection that affected joints are usually those of the lower limb.

## Share With Your Friends





Osseous system Diagram:



Note: Learn All Bone Name its Help in Your Exam and Job Interview



# **Human Anatomy and Physiology Complete Chapter Class**



**Subscribe Our YouTube Channel and Watch  
Complete Videos and Exit Exam Related  
Updates**

**Share With Your Friends**

